

**Revalidatie na
kraakbeenproblemen thv de knie**

OLIVIER BEUCKELAERS

1 OKTOBER 2009
AUDITORIUM KIEKENS, UZ BRUSSEL

Olivier Beuckelaers

- Sportkinesitherapeut
- Orthopedische kine
- Isokinetica
- Heizeltrainer
- Docent sportkine IRSK
- 10 j. profvoetballer bij RWDM
- 4 j. revalidatietrainer RSCA
- Zelfstandig kine Groot-Bijgaarden
- Stagebegeleider sportkine Vub




INHOUD

- KB : Hoe gaan we het aanpakken (Complex) ?
- Principes binnen de revalidatie
- Praktische uitwerking revalidatie
- Progressie in sport (voetbal) na knielijden

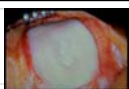

Kraakbeenprobleem – Wat en hoe ?

- Conservatief – Operatief ? (Prof Dr. Handelberg)
- Algemeen
- Belasting * ?
- Open keten – Gesloten keten ?
- Lokale therapie – Algemeen ?
- Schokabsorberende maatregelen *
- Bracing - Unload * ?
- Glucosamines – Hyaluronzuur ?
-




Kraakbeen (hyalien)



- Geen intrinsieke helingscapaciteit (avasculair)
- Kraakbeen kan grote druk weerstaan, maar heeft weinig trekvastheid, in tegenstelling tot bot.
- De kwaliteit van kraakbeen neemt af als het niet belast wordt.
- Kraakbeen geneest door littekenvorming

Functies van het kraakbeen

- Opvang van schokken
- Glijdend vermogen van de beenderstukken
- Aanpassing van het oppervlak om het gewicht optimaal te verdelen. Het kraakbeen kan vervormen en zo de verdeling verbeteren om het goed te laten aansluiten.
- "Spons" van collageen dat synoviaal vocht vast houdt. Ideaal, want vocht is glijdend, schokabsorberend en vormmodulerend.



Visie belasting KB conservatief

- Osteochondritis dissecans
- Tibiaplateau #
- Chondropathie patella
- Meniscushechting

The slide contains four images: two diagrams of a knee joint labeled 'repaired with sutures' and 'repaired with tacks', a grayscale MRI scan of a knee joint, and a 3D anatomical model of a knee joint with a lesion labeled 'Osteochondritis Dissecans'.

Management of osteochondritis dissecans of the knee

We advocate a 3-phase nonoperative management protocol.

The first phase involves knee immobilization for 4 to 6 weeks with crutch-protected, partial weightbearing gait.

In phase 2 (weeks 6-12), weightbearing as tolerated is permitted without immobilization.

If there are radiographic and clinical signs of healing at 3 to 4 months after the initial diagnosis, phase 3 can begin

Kocher, M.S., Tucker, R., Ganley, T.J., Flynn, J.M.
Am J Sports Med, date: 2006, volume: 34, issue: 7, startpage: 1181

Cartilage is a slow adapting substance.

Where a muscle takes approximately 35 weeks to fully adapt itself, cartilage only undergoes 75% adaptation in 2 years

The graph is titled 'Tissue adaptability' and plots 'Adaptation' (y-axis, 0 to 1.0) against 'Time in [weeks]' (x-axis, 0 to 110). Five curves represent different tissues: Muscle (fastest adaptation, reaching 1.0 by ~35 weeks), Bone (reaching 1.0 by ~60 weeks), Ligaments (reaching 1.0 by ~100 weeks), Tendons (reaching 1.0 by ~110 weeks), and Cartilage (slowest adaptation, reaching ~0.75 at 110 weeks).

Oorzaken KB defecten

- Trauma
- Lig. Instabiliteit
- Malalignement (unloader)
- Menisectomie
- Osteochondritis dissecans
- Spierdefecten
- Overbelasting
- Haemarthrose : 15 % relevante defecten
- Bij A'scopie blijkt 63 % KB schade te hebben



Spieren - Cardio ??

Muscle health and muscle rehabilitation are **key components** for the successful prevention of, and recovery from, joint injury and disease.

Lokaal / Ketting

Algemene conditie



Tensegrity – Needle Tower

Schokabsorberende maatregelen

- Rationeel sporten
- Zolen
- Unloader Knee Brace *
- (Over) Gewicht *
- Stilstaan is achteruitgaan



Unloader Knee Brace ???

The researchers found **significant improvements** in patients in the brace and sleeve groups compared with controls, as well as a significant difference between those in the brace and sleeve groups with regard to pain after functional tests.

The long-term benefits of application of the unloader brace for still need to be assessed.

Current Evidence and Clinical Applications of Therapeutic Knee Braces
Chew KTL, Lew HL, Date E, Fredericson M - Am J Phys Med Rehabil 2007; 86: 678-686.

Does Weight Loss Help

Even modest reductions in body weight can significantly reduce the symptoms of joint pain.
5% to 10% reduction of body weight can dramatically reduce joint pain and improve exercise tolerance.

BMI : < 25

Metabool syndroom



Doel van de revalidatie

- Relieve clinical symptoms
- Obtain painless full range of motion
- Obtain good muscle strength
- Improve function.

- Don't overload the healing articular cartilage.

- For a successful outcome, **open communication** should exist between the rehabilitation team and the surgeon.

Postoperatief ACI

- Jonge voetballer met KB-letsel mediale femurcondyl

Proliferatiefase : 7 – 21 dagen
 Differentiatie : 6 – 9 weken
 Maturatie : 9 w – 2 jaar



Buiten fietsen : 3 – 4 maand
 Joggen na 6 – 10 maand
 Voetbal na 16 maanden

Principes binnen de Revalidatie :

- Individualisering
- Reduceren pijn en zwelling
- Herstel R.O.M.
- Herstel homeostase gewricht
- Beweeg : “ motion is lotion for the joint “
- Herstel neuromusculair en proprio
- Opbouw kracht
- KB : “ Soon ripe, soon rotten “

Individualiseren

Letselgebonden


- Lokatie
- Grootte
- Diepte
- Single of gecombineerd

Patiëntgebonden

- Leeftijd
- BMI
- Aligement
- Verleden
- Sport
- A.D.L

Reduceren pijn en zwelling


- Fysiotherapie
- Drainagetechnieken
- Compressie
- Cryotherapie (Aircast)
- Taping (unload patella)



- Reflexinhibitie zoveel mogelijk vermijden

Reflexinhibitie

Intern probleem, zwelling



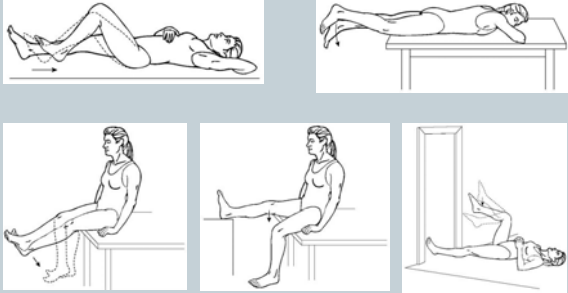
Atrofie Q-ceps, VMO
 VMO bij 20 ml
 Rectus + VL bij 60 ml
 VMO : VL - ratio = < 1/1

Herstel gewricht

- Komen tot een normale R.o.m.
- Eventueel werken met extensiepostures
- Kapsel moet opnieuw soepel worden
- Stretching : harmstrings, heupsieren + kuiten
- Patella mobilisaties
- Stretch Q-ceps + voorste kapsel kan pas later
- Gewricht moet "droog" blijven





Mobiliserende thuisoefeningen



“ Motion is lotion for the joint “

- Beweging is superbelangrijk
- CPM in een vroege fase
- Veel en snel bewegen.
- 30 – 60' fietsen over **grote range** met **low impact**
- Traag bewegen = risico op plastische deformatie
- Progressief meer steunname
- Korte belastingsduur – veel korte sets



Herstel neuromusculair en proprio


- Operatie / lange immobilisatie
- Controle spier → myofeedback
- Dynamische stabiliteit ?
- Positiezin → bewegingszin
- Posturaal evenwicht






Progressie proprio training

- Onbelast → Belast
- Statisch → Dynamisch
- Bipodaal → Unipodaal
- Stabiele ondergrond → Instabiele
- Visus → Geen visus
- Aandacht → Afleiden
- Closed packed → Open

Opbouw kracht

- Starten met éénvoudige settings
- Open keten oefeningen zonder R of gewicht 
- Complex of myofeedback kan nuttig zijn
- Halfopen oefentherapie (Fitter / minivector)
- Bilateraal in gesloten keten (conc + exc) na 6 – 12 w.
- R ↑, door toename n. herhalingen en < sets (6 m)
- Krachttraining = functionele training

Praktische voorbeelden opbouw

Onderdosereren, zeker in het begin









PROGRESSIE IN SPORT NA KNIELIJDEN

1. SPORT ZONDER BELASTING
2. KNIEBELASTING ZONDER ROTATIES
3. KNIEBELASTING MET ROTATIES, ZONDER KONTAKT
4. KNIEBELASTING MET ROTATIES, MET KONTAKT

Cardiovasculaire opbouw na ACI

- Aquatraining * (3 w) – crawl (6w) – school (4m)
- Fietsen : binnen 6w, buiten 3-6 m.
- Wandelen : 10w.
- Nordic -Walking
- Roeien : 3 m.
- Crosstrainer
- Steppen : 3 – 6 m.
- Lopen : 6 – 10 m.



- Kine-praktijk
- Oefenzaal – Fitness
- Revalidatietraining
- Loopvariates + Conditietraining
- Coördinatieoefeningen (The 11+ / Fifa)
- Inschakelen bal – inschakelen duel
- Groepstraining (evt. met opdrachten)
- 100 % training + wedstrijdjes
- Veldtest + evaluatie staf
- Wedstrijdsituatie B kern / A kern

Evolutie na letsel in het voetbal



After these celebrations Stuart Pierce became a woman.

WANNEER GROEPSTRAINING ?

Als de speler er geestelijk klaar voor is

Als de kine-testen positief zijn

Als speler komt aan +/- 90 % vermogen, en dit zowel in Li – Re verhouding als op coördinatief gebied.

Als de medische staf in combinatie met de revalidatietrainer opperen dat hij er klaar voor is.

FUNCTIETESTS A- team + elite (jeugd)

1. **Geen reactie op vorige oefeningen**
2. Hoogtesprong met 1 been (vgl. Li – Re)
3. Vertesprong met 1 been (single hop test)
4. Breedtesprongen (cross-over hop test)
5. Hinken : opwaarts
voorwaarts
achterwaarts
zijwaarts

Kine-testen

Bij deze oef.; altijd de Li – Re verhouding controleren om te kijken naar eventueel restdeficit.

6. Akkoord fysicaal coach : Conditioneel
7. Myotest – Optojump
8. Situatie trainer (verliesmatchen – op de wip ?)
9. Situatie speler (risicoprofiel of eerder rationeel – zie lijst)
10. Veldtest moet voldoen, als de speler daar dan geen hinder van ondervind (ook checken de dag nadien), is hij wedstrijdfit.

8 van de 10 parameters moeten ok zijn om een speler **wedstrijdfit** te verklaren, **veldtest is doorslaggevend**.

Wanneer wedstrijdfit ?

1. Als de speler er geestelijk klaar voor is

2. Als de functietesten * positief zijn

3. Als de veldtest zonder probleem wordt doorstaan

4. Als speler komt aan +/- 95 % vermogen, zowel in Li – Re verhouding als op coördinatief en conditioneel gebied.

5. Als zowel de medische als de technische staf ééndrachtig stellen dat hij er klaar voor is.



CONCLUSIE

- Kniervalidatie waarbij een KB-deficit (beperkende factor) aanwezig is vraagt tijd.
- Druk dient progressief opgebouwd te worden.
- Beweeg veel en snel, over > ROM met low impact
- Gewrichtscirkulatie : minimum 30' – 60' / dag
- Trage bewegingen : risico op plastische deformatie
- Onderdoser, zeker in het begin
- Zwelling of pijn : therapie terugschreven
- Hernemen sport : Rationele visie aanhouden

VRAGEN ???



Bibliografie

Google : Biologic joint reconstruction: alternatives to arthroplasty

- Alford J.W., Cole B.J., Cartilage Restoration, Part 1. Am J Sports Me. Vol. 33, No. 2, pp. 295 - 306, 2005.
- Alford J.W., Cole B.J., Cartilage Restoration, Part 2. Am J Sports Me. Vol. 33, No. 3, pp. 443 - 460, 2005.
- Baydar, M., Gülbahar, S., Physical therapy and rehabilitation in chondral lesions. Acta Orthop Traumatol Turc, Vol. 41, Suppl 2, pp. 54 - 61, 2007.
- Brindle T., Nyland J., Johnson D.L., The Meniscus: Review of Basic Principles With Application to Surgery and Rehabilitation. Journal of Athletic Training Vol. 36, No. 2, pp. 160 – 169, 2001.
- Chew K.T.L., Lew H.L., Date E., Fredericson M., Current Evidence and Clinical Applications of Therapeutic Knee Braces. Am J Phys Med Rehabil, Vol. 86, pp. 678 – 686, 2007.
- Chimal A., Davids M., Valpoort N., Het recept voor een sportrevalidatie model – Opleiding Fysiotherapie. Hogeschool van Amsterdam , 2006.

Bibliografie 2

- Chow J. C.Y., Hantes ME., Houle JB., Zalavras CG.. Arthroscopic Autogenous Osteochondral Transplantation for Treating Knee Cartilage Defects: A 2- to 5-Year Follow-up Study. *The Journal of Arthroscopic and Related Surgery*, Vol. 20, No. 7, pp 681 – 690, 2004.
- Ebert J.R., Robertson W.B., Lloyd D.G., Zheng M.H., Wood D.J., Ackland T.. Traditional vs accelerated approaches to post-operative rehabilitation following matrix-induced autologous chondrocyte implantation (MACI): comparison of clinical, biomechanical and radiographic outcomes. *Osteoarthritis Cartilage*, Vol. 16, No. 10, pp. 1131 -1140, 2008.
- Fulkerson J.P.. Diagnosis and Treatment of Patients with Patellofemoral Pain. *Am J Sports Med*, Vol. 30, No. 3, pp. 447 - 456, 2002.
- Getgood A., Bhullar TPS., Rushton N.. Current concepts in articular cartilage repair. *Orthopaedics and Trauma*, Vol. 23, No. 3, pp. 189 - 200, 2009.
- Hambly K.. Articular Cartilage Repair of the Knee. <http://www.cartilagehealth.com/acr.html>.
- Hambly K.. Knee articular Cartilage Repair and Athletes. *Sportfelf Medicine*, Vol. 39, pp. 17 - 21, 2009.
- Hambly K., Bobic V., Wondrasch B., Van Assche D., Marlovits S.. Autologous Chondrocyte Implantation Postoperative Care and Rehabilitation. *Am J Sports Med.*, Vol. 34, No. 6, pp. 1020 – 1038, 2006.

Bibliografie 3

- Herzog W., Longino D., Clark A.. The role of muscles in joint adaptation and degeneration. *Langenbecks Arch Surg*, Vol. 288, pp. 305 – 315, 2003.
- Holmes S., Wendell Jr.. Articular cartilage injuries in the athlete's knee: current concepts in diagnosis and treatment. *Southern Medical Journal*, 2004.
- Hooiveld M., Roosendaal G., Wenting M., van den Berg M., Bijlsma J., Lafeber F.. Short-Term Exposure of Cartilage to Blood Results in Chondrocyte Apoptosis. *American Journal of Pathology*, Vol. 162, No. 3, pp. 943 – 951, 2003.
- Hubbard T.J., Denegar C.R.. Does Cryotherapy Improve Outcomes With Soft Tissue Injury? *Journal of Athletic Training*, Vol. 39, No. 3, pp. 278 – 279, 2004.
- Hunziker E.B.. Articular cartilage repair: basic science and clinical progress. A review of the current status and prospects. *Osteoarthritis and Cartilage*, Vol. 10, pp. 432 – 463, 2001.
- Jakobsen R.B., Engbretsen L., Slauterbeck J.R.. An Analysis of the Quality of Cartilage Repair Studies. *The Journal Of Bone and Joint Surgery*, Vol. 87-A, No. 10, pp. 2232-2239, 2005.
- Jansen N.W.D., Roosendaal G., Bijlsma J.W.J., DeGroot J., Theobald M., Lafeber F.P.J.G.. Degenerated and healthy cartilage are equally vulnerable to blood-induced damage. *Ann Rheum Dis*, Vol. 67, pp. 1468 – 1473, 2008.
- Jansen N.W.D., Roosendaal G., Bijlsma J.W.J., DeGroot J., Lafeber J.P.J.G.. Exposure of Human Cartilage Tissue to Low Concentrations of Blood for a Short Period of Time Leads to Prolonged Cartilage Damage - An In Vitro Study. *Arthritis & Rheumatism*, Vol. 56, No. 1, pp. 199-207, 2007.

Bibliografie 4

- Kocher M.S., Tucker R., Ganley T.J., Flynn J.M.. Management of Osteochondritis Dissecans of the Knee. *Am J Sports Med*, Vol. 34, No. 7, pp. 1181 - 1191, 2006.
- Kon E., Gobbi A., Filardo G., Delcogliano M., Zaffagnini S., Marcacci M.. Arthroscopic Second-Generation Autologous Chondrocyte Implantation Compared With Microfracture for Chondral Lesions of the Knee. *Am J Sports Med*, Vol. 37, No. 1, pp. 33 – 41, 2009.
- LaPrade R.F., Bursch L.S., Olson E.J., Havlas V., Carlson C.S.. Histologic and Immunohistochemical Characteristics of Failed Articular Cartilage Resurfacing Procedures for Osteochondritis of the Knee. *Am J Sports Med*, Vol. 36, No. 2, pp. 360 - 368, 2008.
- Makdissi M., Eriksson K.O., Morris H.G., Young D.A.. MRI-negative bucket-handle tears of the lateral meniscus in athletes: a case series. *Knee Surg Sports Traumatol Arthrosc*, Vol. 14, pp. 1012 – 1016, 2006.
- Martinek V., Friederich N.F.. To brace or not to brace? *Orthopäde*, Vol. 28, pp. 565 – 570, 1999.
- McGinty C., Irrgang J.J., Pezullo D.. Biomechanical considerations for rehabilitation of the knee. *Clinical Biomechanics*, Vol. 15, pp. 160 – 166, 2000.
- Mithöfer K., Peterson L., Mandelbaum B.R., Minas T.. Articular Cartilage Repair in Soccer Players With Autologous Chondrocyte Transplantation. *Am J Sports Med.*, Vol. 33, No. 11, pp. 1639 – 1646, 2005.
- Mithöfer K., Minas T., Peterson L., Yeon H., Micheli L.J.. Functional Outcome of Knee Articular Cartilage Repair in Adolescent Athletes. *Am J Sports Med*, Vol. 33, No. 8, pp. 1147 - 1153, 2005.

Bibliografie 5

- Mithöfer K, Williams III R.J., Warren R.F., Wickiewicz T.L., Marx R.G., High-Impact Athletics After Knee Articular Cartilage Repair. *Am J Sports Med.* Vol. 34, No. 9, pp. 1413 - 1418, 2006.
- Moretti B., Notarnicola A., Moretti L., Giordano P., Patella V.. A volleyball player with bilateral knee osteochondritis dissecans treated with extracorporeal shock wave therapy. *Musculoskelet Surg.*, Vol. 93, pp. 37 - 41, 2009.
- Riegger-Krugh C.L., McCarty E.C., Robinson M.S., Wegzyn D.A., Autologous Chondrocyte Implantation: Current Surgery and Rehabilitation. *Med. Sci. Sports Exerc.*, Vol. 40, No. 2, pp. 206-214, 2008
- Roosendaal C., Vianen M.E., Marx J.J.M., Van Den Berg H.M., Lafeber F.P.J.G., Bijlsma J.W.J., Blood-Induced Joint Damage - A Human In Vitro Study. *ARTHRITIS & RHEUMATISM*, Vol. 42, No. 5, pp. 1025-1032, 1999.
- Slynarski K., Deszczynski J., Algorithms for Articular Cartilage Repair. *Transplantation Proceedings*, Vol. 38, pp. 316-317, 2006.
- Yildiz Y., Aydin T., Sekir U., Cetin C., Ors F., Kalyon T.A., Relation between isokinetic muscle strength and functional capacity in recreational athletes with chondromalacia patellae. *Br J Sports Med.* Vol. 37, pp. 475 - 479, 2003.
- Zaslav K., Cole B., Brewster R., DeBerardino T., Farr J., Fowler P., Nissen C., A Prospective Study of Autologous Chondrocyte Implantation in Patients With Failed Prior Treatment for Articular Cartilage Defect of the Knee. *Am J Sports Med.* Vol.37, No. 1, pp. 42 - 55, 2009.

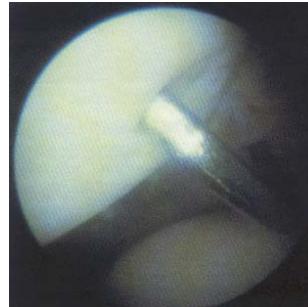


Cartilage lesions: Treatment

F. Handelberg UZ Brussel



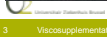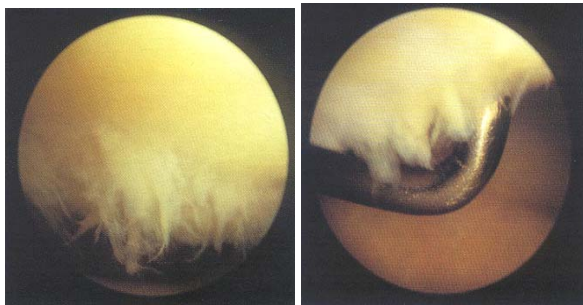Cartilage softening – grade 1



2 Viscosupplementation

24-04-2009

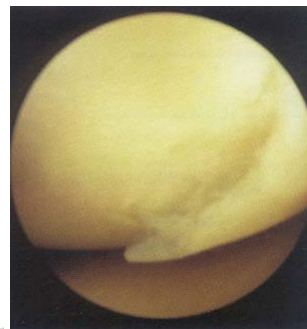Fraying - grade 2



3 Viscosupplementation

24-04-2009

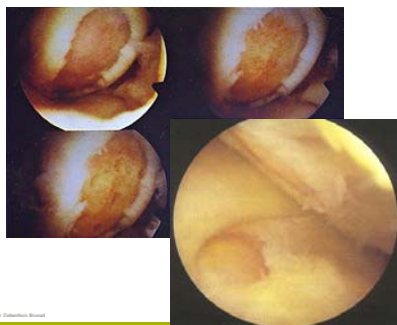
Deep lesion - grade 3



4 Viscosupplementation

24-04-2009

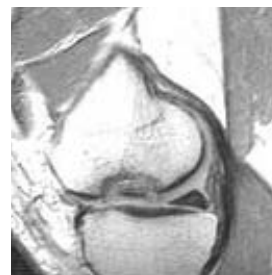Deep lesion - grade 4



5 Viscosupplementation

24-04-2009

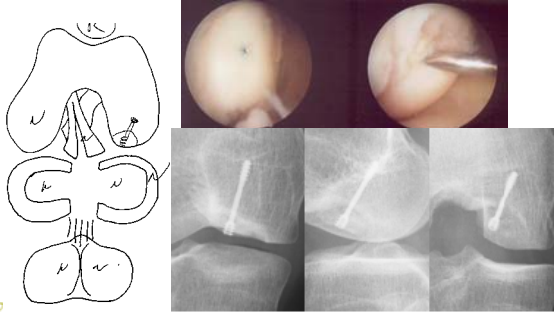
Osteochondritis dissecans



6 Viscosupplementation

24-04-2009

Refixation of loose fragment

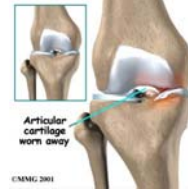

Viscosupplementation

24-04-2009

Osteoarthritis

- Chronic degenerative disorder
 - Joint pain & loss of joint function
- Common disease to affect synovial joints
- Most frequently occurring chronic conditions



Viscosupplementation

24-04-2009

Kellgren-Lawrence Grading Scale

Grade 1: doubtful narrowing of joint space and possible osteophytic lipping

Grade 2: definite osteophytes, definite narrowing of joint space

Grade 3: moderate multiple osteophytes, definite narrowing of joints space, some sclerosis and possible deformity of bone contour

Grade 4: large osteophytes, marked narrowing of joint space, severe sclerosis and definite deformity of bone contour



Viscosupplementation

24-04-2009

Osteoarthritis treatment

- Primary goal: alleviation of pain
 - Improvement of joint function
 - Improvement of quality of life
- Options are:
 - Conservative therapies: education, weight loss, physical therapy, ...
 - Pharmacological therapies: simple analgesics, NSAIDs
 - Intra-articular injections: cortico-steroids, viscosupplements

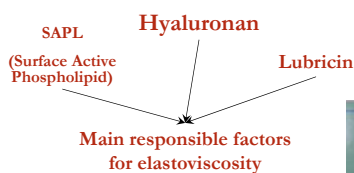


Viscosupplementation

24-04-2009

What is viscosupplementation?

- Hyaluronan = Natural Glycosaminoglycan in synovial fluid



Viscosupplementation

VISCOSUPPLEMENTATION

Working mechanism is probably a combination of factors

- Restoration in joint rheology
- Antinociceptive effects
- Normalization of Hyaluronan synthesis

JOINT HOMEOSTASIS



Viscosupplementation

Viscosupplementation

- Widely studied

- Marshall: 92 patients
 - 77% with severe OA
 - 68% did not go on to arthroplasty during 2.5 y and were considered as "salvaged"
- Kotevoglou: comparative trial different molecular weight HA versus placebo
 - WOMAC stiffness score and Patient Global Assessment better in HA than in placebo
 - Physician Global assessment worse in placebo
 - HA groups did not differ in terms of efficacy, but higher molecular weight might be more efficacious



13 Viscosupplementation

24-04-2009

Indications

- More than 90% of patients with symptomatic OA of the knee have evidence of degenerative meniscal tears on MRI
- Arthroscopic lavage & meniscal debridement can be used to treat patients who are unresponsive to more conservative therapies, but are not knee-arthroplasty candidates yet
- But perhaps this will have a deleterious effect and will precipitate OA in patients over 65!



14 Viscosupplementation

24-04-2009

Indications of viscosupplementation

- Patients with moderate OA
 - Normal mobility
 - Standing X-rays: Kellgren-Lawrence grade I or II
 - Not responding to conservative measures
 - On MRI showing cartilage lesions Grade II or III
 - Normal axis and under 55 y old
 - Not reluctant to undergo surgery
 - If significant meniscal lesions are detected on MRI, first perform arthroscopy



15 Viscosupplementation

24-04-2009

BELGIUM ARTHROSCOPY ASSOCIATION



Hylan G-F 20 injections in the treatment of pain following arthroscopic meniscal resection in osteoarthritis patients

Results of a prospective multi-center clinical trial

F. HANDELBERG (Brussels - Belgium)
J-P. HUSKIN (Liège - Belgium)



Conclusions of this study



- Synvisc was efficacious in patients with early knee OA presenting with pain 4-12 weeks after arthroscopic meniscectomy :
 - Walking pain VAS
 - Patient and investigator global assessments
 - WOMAC indexes
- Symptomatic efficacy increased up to the week 26 endpoint and was maintained throughout the study up to the week 52 endpoint
- The most common related AE's were target knee AEs as pain, swelling and effusion



Our conclusions

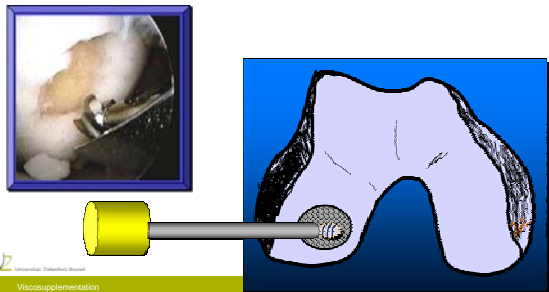


- Study confirms 6+ months efficacy of additional Synvisc® injections after arthroscopy for mechanical symptoms in patients with early OA
 - Benefit in pain
 - Benefit in function
 - Benefit in increasing activity level and sports participation?



Surgical options

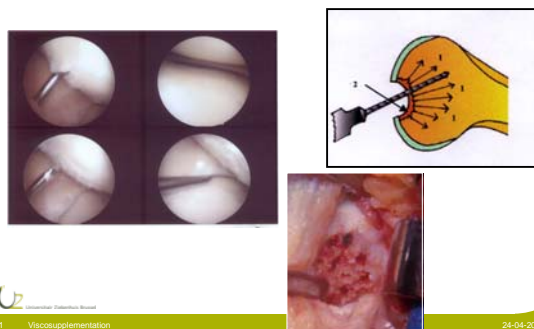
- Arthroscopic Lavage
- Shaving / debridement / abrasion



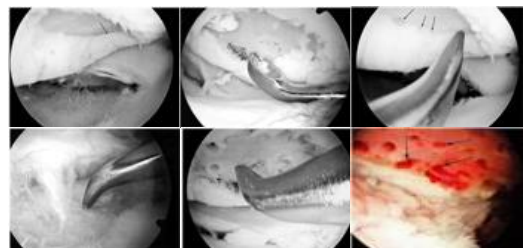
BONE MARROW STIMULATION by perforation of subchondral plate

- **Drilling of the subchondral bone**
– K. H. Pridie
- **Abrasion arthroplasty** – L. L. Johnson
- **Microfracture** – R. J. Steadman

Pridie-technique



Microfracture-technique: icepicking



Disadvantages:

- Creation of a hyaline-like tissue
- This fibrocartilaginous tissue can soon start to degenerate !

Surgical options

- Arthroscopic Lavage
- Shaving / debridement / abrasion
- Pridie / icepicking
- **Cartilage repair in young**

Cartilage repair: „New ways”

- periosteal flapping
 - Rubak, O’Driscoll, Lorentzon
- perichondrial flapping
 - Coutts, Homminga, Bruns
- *Alone or in combination with other techniques*



Cartilage repair: „New ways”

- periosteal flapping
 - Rubak, O’Driscoll, Lorentzon
- perichondrial flapping
 - Coutts, Homminga, Bruns
- *In combination with chondrocyte implantation*
 - Green, Brittberg, Petersen



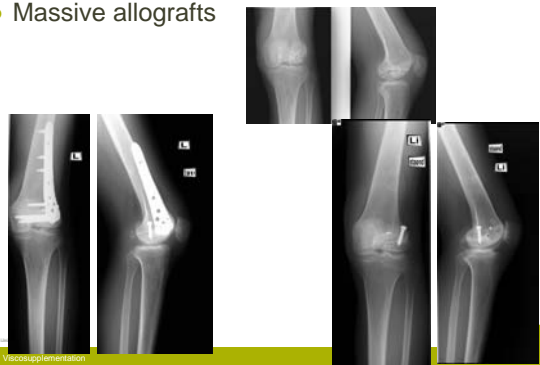Cartilage repair: „New ways”

- allografts
 - Lexer, Convery, Mankin, Gross, Reagan
- autografts
 - Krompecher, Fabricciani, Yamashita, Wagner



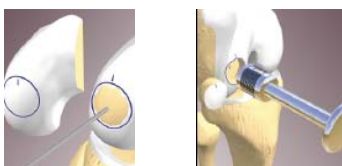
Allografts

- Massive allografts

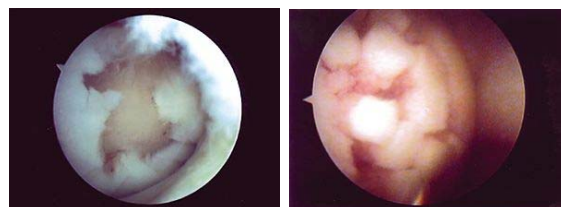


Allografts

- Massive allografts
- Allograft OATS

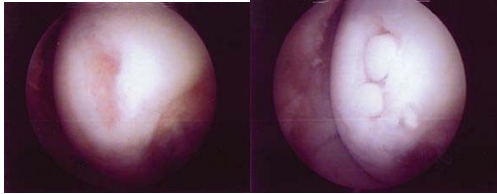


Autografts: Mozaicplasty and OATS



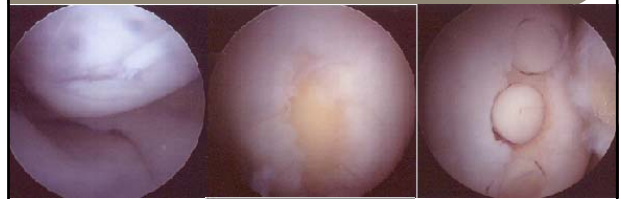Surgical options

OATS= Osteochondral Autograft Transfer System



31 Viscosupplementation

24-04-2009

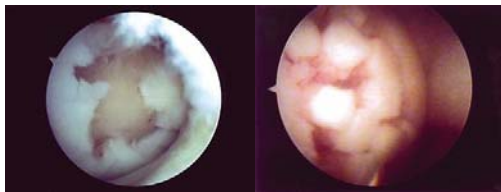


32 Viscosupplementation

24-04-2009

Surgical options

- Mosaicplasty



33 Viscosupplementation

24-04-2009

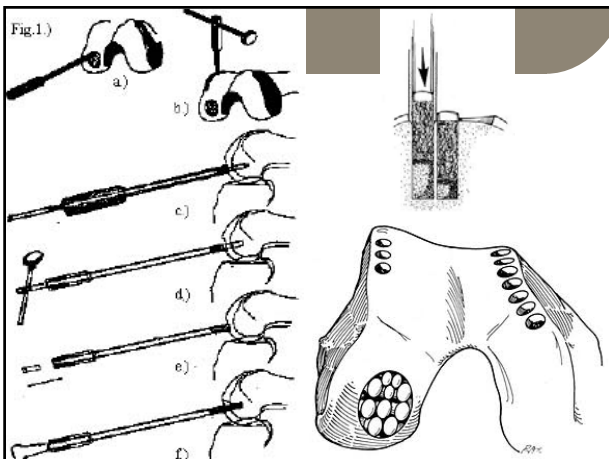
Indications

- symptomatic, focal chondral or osteochondral defects **1.0 – 4.0 cm²**
- age: under 50
- parallel treatment of the underlying cause
- Requirements at the indication:
 - no osteoarthritic changes
 - no kissing lesions
 - no tumor or synovial disease

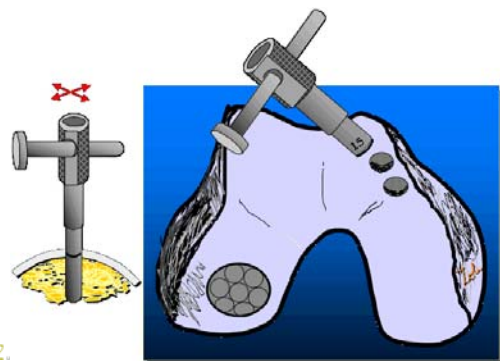


34 Viscosupplementation

24-04-2009



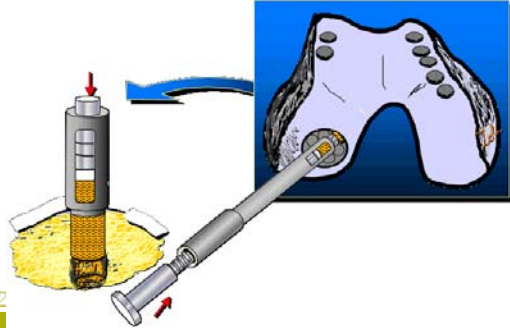
Prelevation



36 Viscosupplementation

24-04-2009

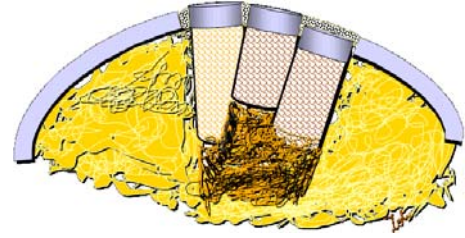
Implantation



97

2009

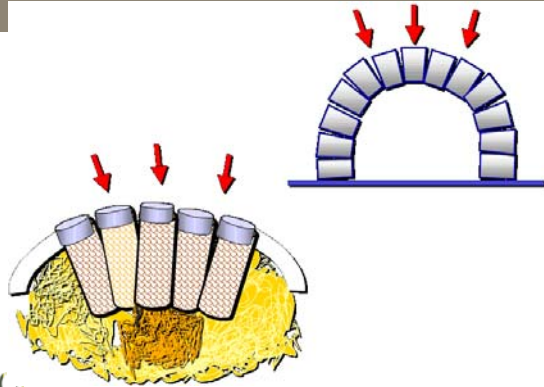
Respect congruency



98

Viscosupplementation

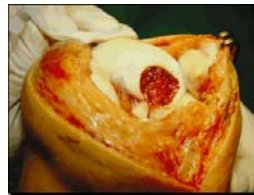24-04-2009



39

Viscosupplementation

24-04-2009



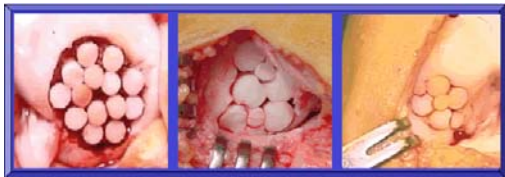40

Viscosupplementation

24-04-2009

Technique

78,5% 90% ~100%

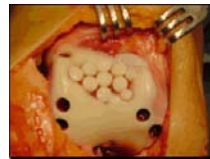
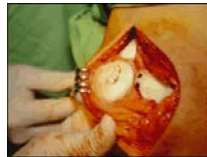
41

Viscosupplementation

24-04-2009

Patella or trochlea



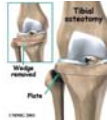42

Viscosupplementation

24-04-2009

Concomitant procedures to treat the underlying causes:

- ACL reconstruction
- femorotibial realignment osteotomies
- meniscus surgery
- correction of the patellofemoral tracking
- patellar and trochlear osteotomies



Basic problems of autologous osteochondral grafting:

- lack of the appropriate donor area
- congruency problems
- technical difficulties
- **Decrease in cell volume and cell density near the iatrogenic lesion (necrosis and apoptosis) + absence of lateral support to the plugs → cartilage degeneration**

Autologous chondrocyte implantation

- Carticel (Genzyme)
- Chondrocelect (Tigenix)
- **In vitro propagation of autogenous chondrocytes**

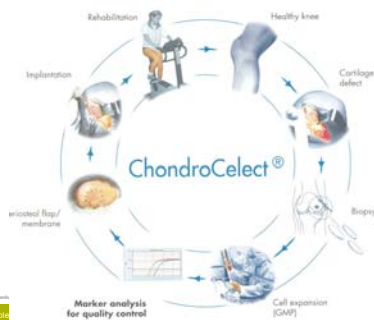
Autologous chondrocyte implantation

Carticel™ Treatment

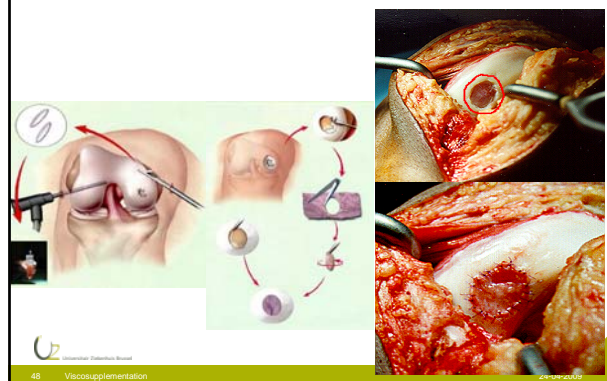
1. Healthy cartilage biopsy taken from patient
2. Biopsy sent to Genzyme Tissue Repair for processing
3. Cultured cells sent to surgeon
4. Cultured cartilage cells injected under periosteal flap


periosteal flap, taken from lower leg bone and sutured on top of defect

ChondroCelect



Autologous chondrocyte implantation





TISSUCOL 3 douages

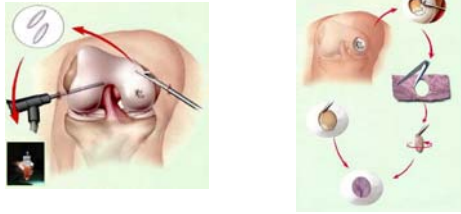
TISSUCOL KIT 2 x 20

Prolene 7/0

49 Viscosupplementation 24-04-2009

Autologous chondrocyte implantation: disadvantage

2 stage procedure: 1/ biopsy 2 /open implantation



50 Viscosupplementation 24-04-2009

Autologous chondrocyte implantation: disadvantages

2 stage procedure with 4 weeks in between

Maturation of cartilage takes 2 years!

Periosteal flap can be replaced by a bioresorbable collagen membrane (expensive !)

Total cost : 9000 €!!!

51 Viscosupplementation 24-04-2009

ChondroCelect-P

- Introducing stem cell technology to replace cartilage biopsy...

52 Viscosupplementation 24-04-2009

Transplantation of cells encapsulated in a scaffold

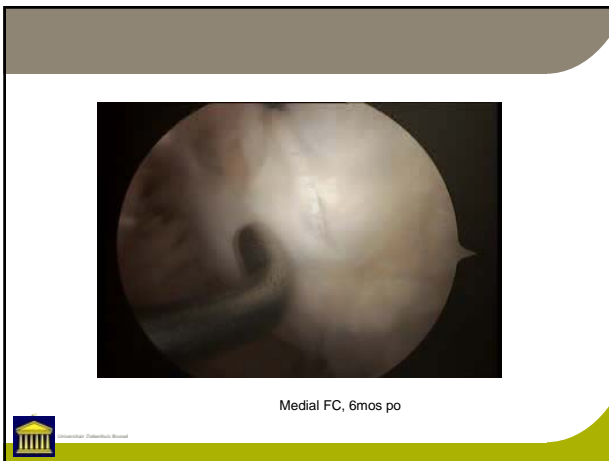
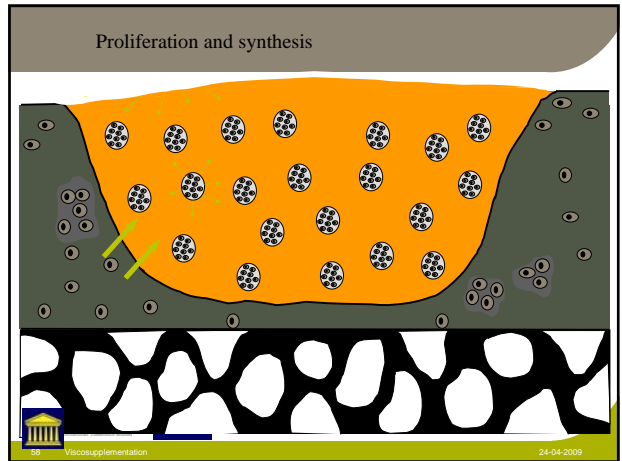
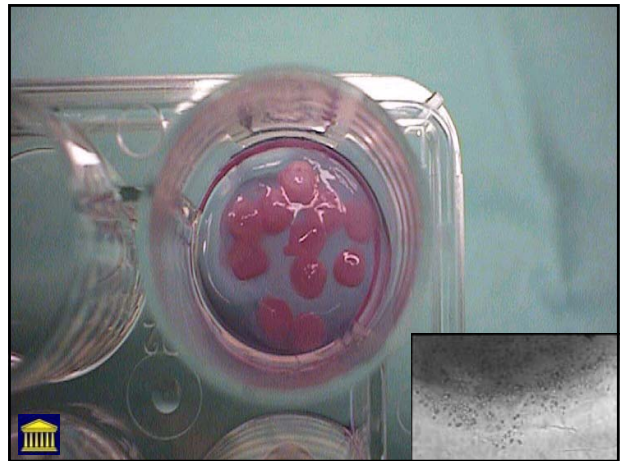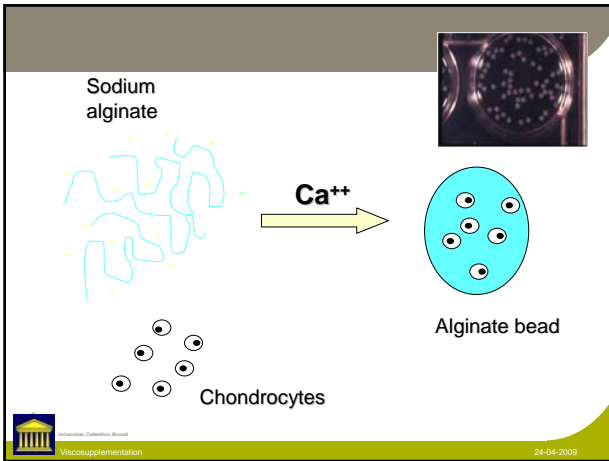
- Thanks to tissue-engineering, **autogenous or allogeneous chondrocytes** can be cultured in **biodegradable and biocompatible three-dimensional matrices** where the chondrocytes remain phenotypically stable and are **able to proliferate** and **synthesize** an extracellular matrix containing cartilage-specific molecules (aggrecan, type II collagen)

53 Viscosupplementation 24-04-2009

Allografts ? Homologous cartilage implantation

- Hydrogels: ex. Agarose, Alginate
- Cartilage beads (not liquid substance)
- Almqvist: allogeneic chondrocytes cultured for 10-14 days in alginate, then implanted under a periosteal flap
- Advantage: only one stage !

54 Viscosupplementation 24-04-2009



Arthroscopy ?

- Arthroscopic implantation of hyaluronic acid in a modified form (solid) has been described

Viscosupplementation 24-04-2009

Arthroscopy ?

- Arthroscopic implantation of hyaluronic acid in a modified form (solid) has been described
- Arthroscopic Chondrocyte implantation

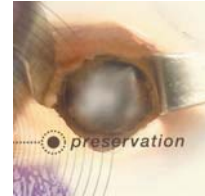


61 Viscosupplementation

24-04-2009

Arthroscopy ?

- Mini-metal prosthesis on the market yet: ArthroSurface Hemicap



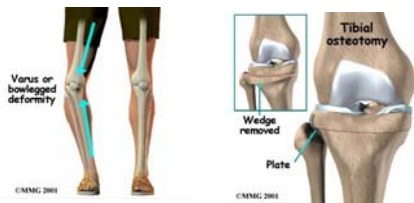Diam.: 25 & 30 mm

62 Viscosupplementation

24-04-2009

Surgical options in Osteoarthritis treatment

- Tibial or femoral osteotomy < age of 55

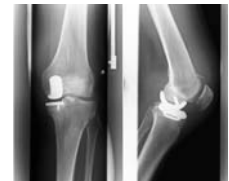
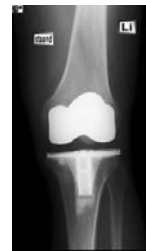
63 Viscosupplementation

24-04-2009

Surgical options in Osteoarthritis treatment

- Knee arthroplasty
 - Partial unicompartmental
 - Total tricompartmental



64 Viscosupplementation

24-04-2009